

Different imaging techniques used in otolaryngology

Kirti Somani¹, Nupur Tewari², Khandakar Faridar Rahman³, Saurabh Mukherjee⁴

M.tech. Scholar¹, M.tech. Scholar², Assistant professor³, Associate professor⁴

Department of Computer Science, AIM & ACT, Banasthali University, Rajasthan, India

Abstract

This article deals with the different imaging techniques that are used for the ear, nose, and throat. With the advancement in medical image processing, there are various imaging techniques such as x-rays, Magnetic resonance imaging, computed tomography, nuclear medicine, single photon emission computed tomography, positron emission tomography etc. In this article, we talk about the various imaging techniques, how they work, their advantages over others techniques, their disadvantages etc. Also which imaging techniques are preferred during various ENT diseases, which are used for diagnosis purposes and how they are helpful in planning the precise treatment?

Keywords- computed tomography scan, magnetic resonance imaging, ultrasound/ultrasonography, positron emission tomography and single photon emission computed tomography

Introduction

During the discovery of x-rays in late 1800's, radiology study had very little role to play for the diagnostic assessment in many of the neck and head diseases. The main reason was that, x-ray used to give false conclusion and doctors was not supposed to rely on them.

But after the introduction of modern tomography imaging and medical image processing, diagnostic assessment of head and neck disease become quite easy and reliable. Here the tomography refers to the imaging by section, using a penetrating any kind of wave. The modern tomography imaging includes computed tomography scan, magnetic resonance imaging, ultrasound/ultrasonography, positron emission tomography and single photon emission computed tomography. These imaging

modalities also come under the medical imaging which is a part of biological imaging in combination with radiology.

The popularization of these imaging techniques was due to their precise, non-overlapping and non-distorted visualization of head and neck with high contrast and spatial resolution. These imaging helps doctors to detect the spatial extent of disease, anatomical danger area and help in planning of surgery, precise an appropriate treatment.

Imaging Techniques

1. Computed tomography scan

Computed tomography is one of the most popular imaging techniques, abbreviated as CT or CAT (computed axial tomography). It is a kind of imaging test that is often recommended by doctors to diagnose a range of condition. Reason the computed tomography is popular because of its details that it give to the doctors about what is actually happening in the human body. They help doctors to identify internal body structure, its size, structure texture. Its advantage over x-ray was that it eliminates the overlap structures that happen in x-ray. They are widely and mainly useful for the diagnosis of cancer.

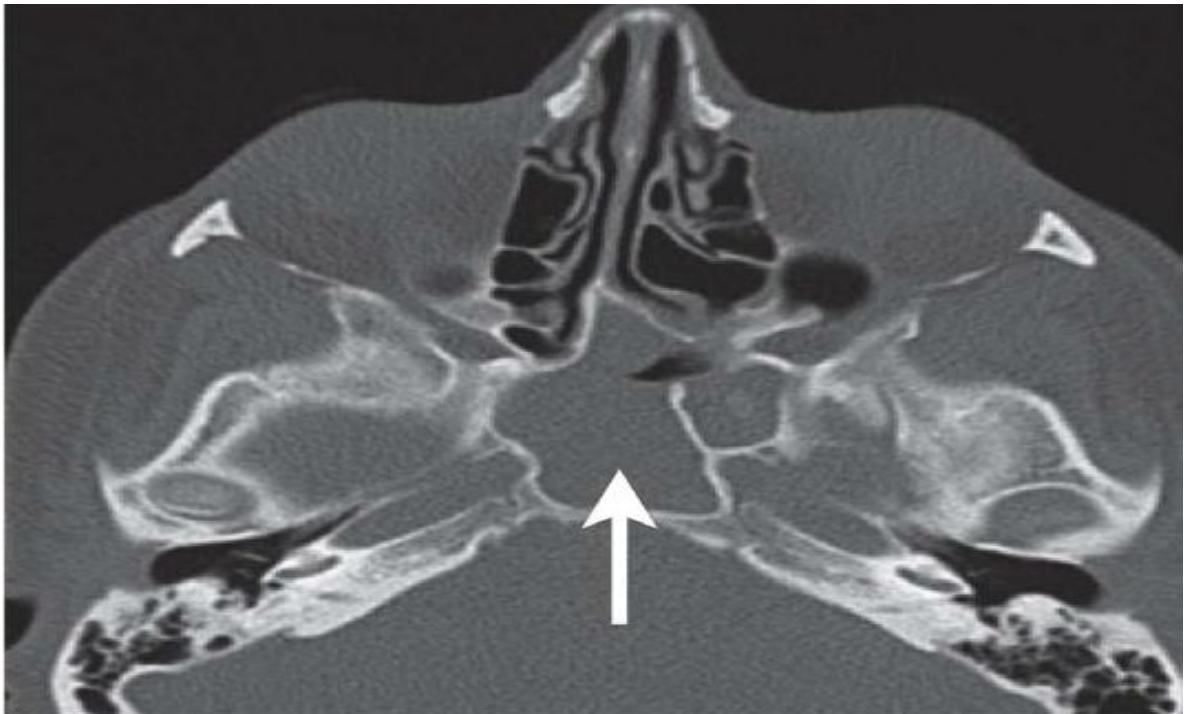
Advantages of computed tomography are that they are highly accurate and play an important role in helping doctors to diagnose the disease. It is painless procedure that record and take pictures of bones, tissues and blood vessels throughout the body and produce a high quality image. Computed tomography also provides real time imaging and helps doctor to view 3d images.

Comparing with other imaging techniques, the demerit with computed tomography is large expose of radiation to the patient going through computed tomography. Apart from this, sometimes before scan patients receive a dose of contrast material, containing iodine. Some people are allergic to this and experience its side effects

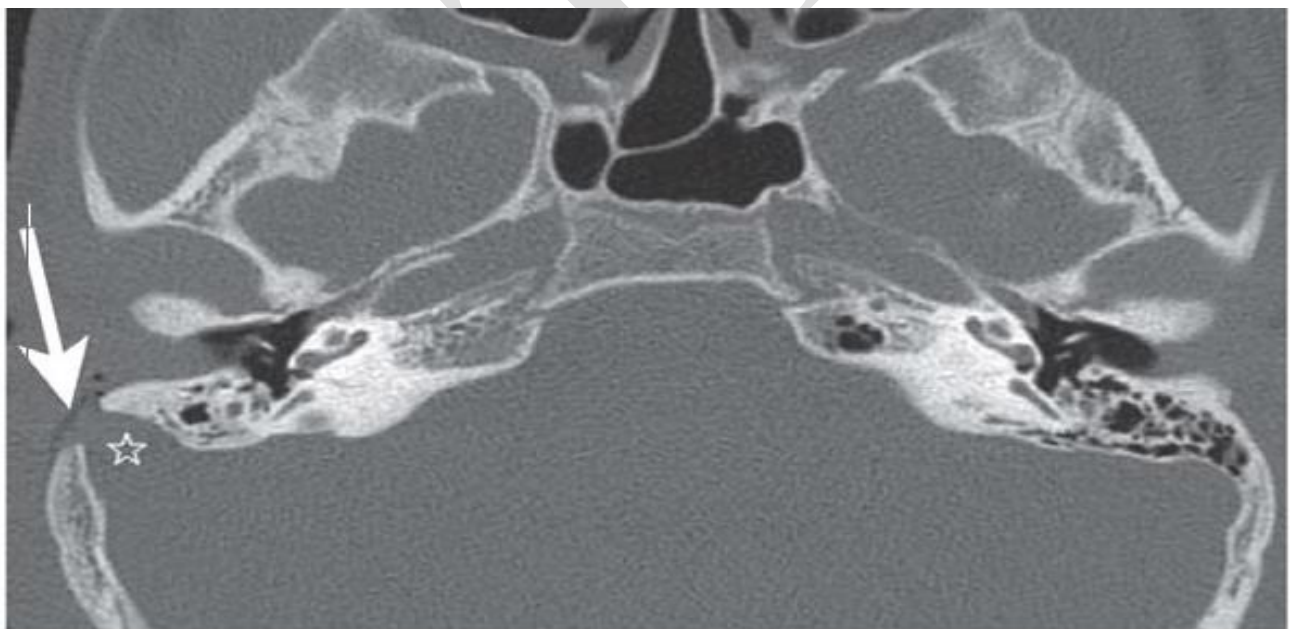
Computed Tomography is widely used for initial stages of the disease in ear, nose and throat. Computed tomography scanning is done to evaluate petrous and mastoid portion of temporal bone, e.g. Hearing loss, face palsy, including acquired diseases –especially inflammatory traumatic, and neoplastic processes of inner, middle and outer ear. CT helps in determining the extent of bony destruction in disease like cholesteatoma, mastoid, and tumors.

CT scanning of neck is standard for emergency evaluation of suppurative head and neck lesion.

Whereas CT scan for nose is done during sinuses or chances of nose cancer.



(i) *CT of paranasal sinuses[3]*



(ii) *CT of petrous bone.[3]*

2. Magnetic Resonance Imaging(MRI)

Magnetic Resonance Imaging is a technique of medical imaging which is used in radiology to form the picture of the human anatomy. These scanner use strong magnetic field, radio waves,

and field gradients to generate the inside images of a body. Since its early development, MRI has proven to be quite versatile imaging modality. While most of MRIs are used in diagnostic medicine and medical research, it can be also used to form images of non living object.

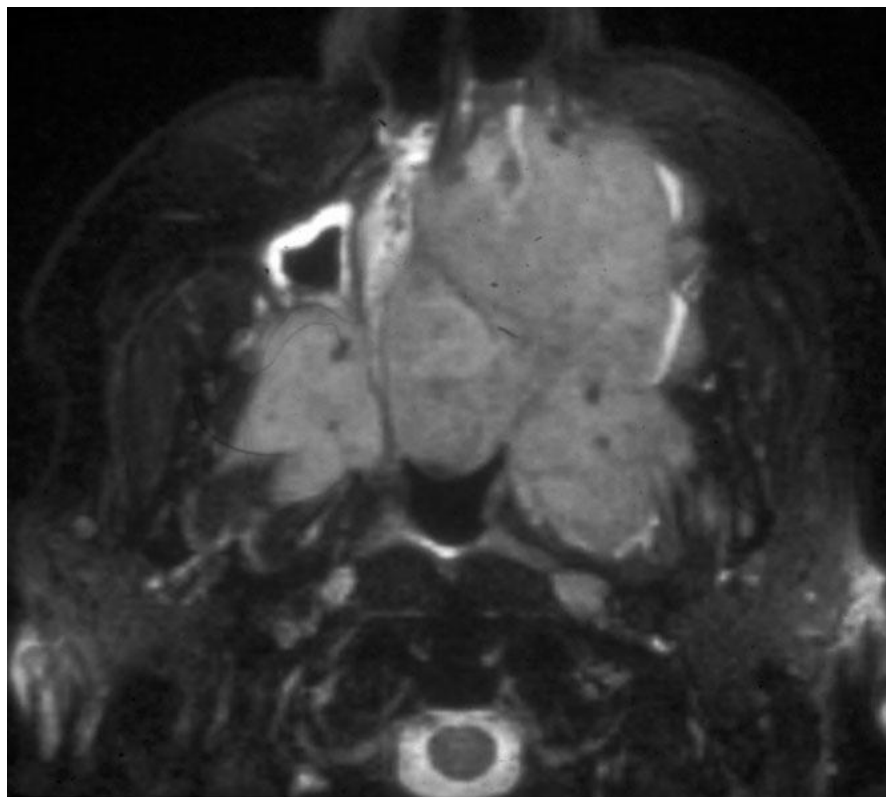Apart from a normal magnetic resonance imaging scan there are other specialized forms of MRI also that provide additional information to the doctors. Other specialized forms of MRI scans are such as diffusion weighted MRI, Turbo spin echo MRI, dynamic contrast enhanced MRI, magnetic resonance angiography, magnetic resonance spectroscopy and perfusion MRI.

MRI scans can be used for most ailments of brain such as tumors, vascular abnormalities, female pelvic problem, prostate problem, soft tissues and bone and certain ear, nose and throat problems.

Benefits of MRI scans are that they provide a very detailed diagnostic picture of the organs and tissues in the body, also able to show some unique feature that are not able to do by other test. Scans are fast, painless and non-invasive. Also big benefits with MRI scans are that they do not use ionizing radiation.

Generally there are no harmful effects of MRI but there are some precautions that are needed to be taken such as MRI are avoided in the first 12 weeks of pregnancy, undetected metal implants such as cochlear implant or pacemaker may be affected by MRI magnetic field. Gadolinium is injected sometime to the patients before MRI scans and there are rare risks of complication with gadolinium to the patients that have kidney disease.

In the head and neck disease, MRI is mainly used during the pre and post operative tumor imaging. Particularly in the ear disease, cholesteatoma, MRI and other specialized form of MRI scans play very important role as scans can avoid the second look surgery. MRI is also a method of choice to assess anomalies of inner ear diseases. During the benign tumor in salivary gland and if the lesion is suspected to be neoplastic, MRI is preferred over other modalities as it provide an excellent assessment of tumor. MRI of thyroid gland is done and shows nodular non-homogeneity as well as contrast enhancement.



(iii)MR image of nasal cavity. [4]

3. Positron emission tomography scan

Positron emission tomography, also known as PET scan or PET imaging is a type of nuclear medicine imaging. It is done by the doctor to check the disease in patient's body. It is an effective way to examine the chemical activity in patient's body.

As it is a type of nuclear medicine imaging, it uses a radioactive material to diagnose and determine the extent or severity of disease. Its procedure helps to pinpoint the molecular activity in the human body offering to identify the disease in its earliest stage.

A PET scan measures blood flow, oxygen use, glucose levels etc. PET scan is majorly used for the detection of cancers, heart problems, effect of heart problems, and brain abnormalities such as tumors, memory disorders.

Benefits of PET scan is as it is a part of nuclear medicine it provides unique and exact information , including details of both function and anatomic structure of body .It is less expensive and may yield more precise result. As it helps in identifying body changes as molecular level, it detects the disease at early stages.

There is no major risk involve during PET scan apart from mild radioactive tracers, which rarely causes any side effects.PET scans can be useful in staging and monitoring the head and neck

tumors. Also helpful in temporal bone cancer, plays an important role in diagnosing laryngeal and hypo pharyngeal cancers.

4. Ultrasonography

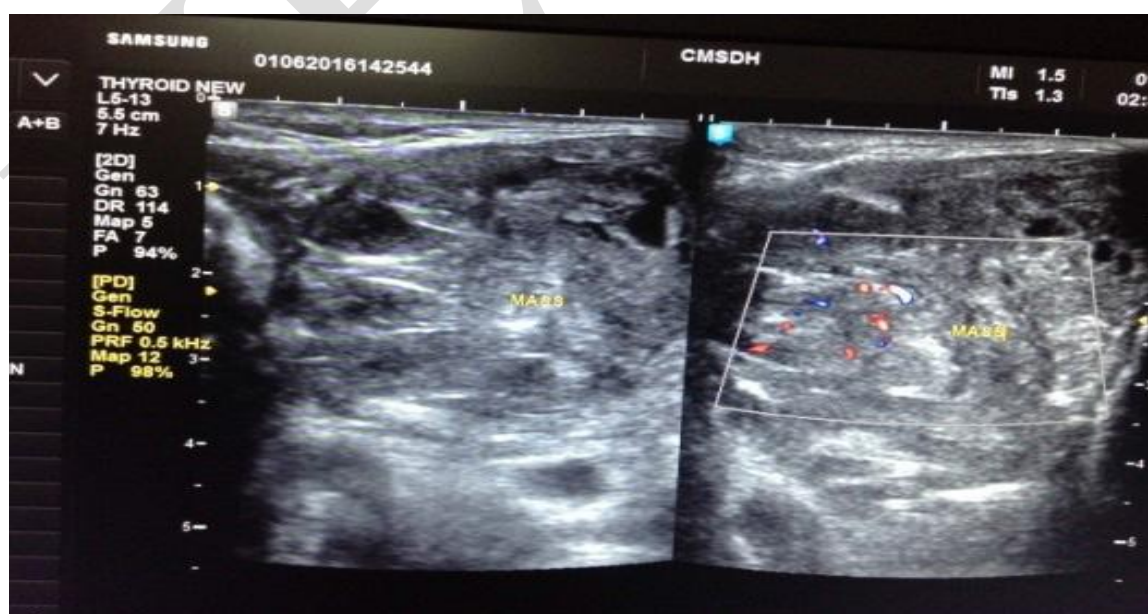
Medical ultrasound, also known as ultrasonography is imaging technique used for diagnostic purpose is based on application of ultrasound. It is mainly used to diagnose internal structures such as tendons, muscles, vessel, joints and internal organs.

Ultrasound imaging takes the help of sound waves to pictures of the inside of body. It is a noninvasive medical test and displays the images in thin, flat section of the body. Recent advancement in ultrasound is 3D ultrasound.

Doppler ultrasound is a part of ultrasound examination. There are 3 types of Doppler ultrasound named a: color Doppler, power Doppler, and spectral Doppler.

Ultrasonography has lot of benefits like it is a noninvasive, no needles or injections, widely available and easy to use, gives clear pictures of soft issue , do not use ionizing radiations , real time imaging. There are no known major demerits of ultrasound according to diagnostic standards.

Ultrasound otolaryngology is quite useful because clinical findings can be misleading. It is a valuable tool for diagnosing of peritonsillar abscess, a deep infection of face and neck, odontogenic facial abscesses, and in the assessment of neck masses. Ultrasound is used for throat problems such as throat cancer, increased lymph nodes, and thyroid problems.



(iv) Grayscale and color Doppler assessment of neck masses [7]

5. Digital Volume Tomography

Digital volume tomography is one of kind of CBCT, Cone beam computed tomography, and it also enables 3d images of osseous structures. It is a sectional imaging technique which is quite similar to computed tomography and was first used only for dental diagnosis, teeth and jaws.

The advantages of digital volume tomography are high spatial resolution and low ionize radiation and reduced metal effect.

The role of DVT in otolaryngology is not much, it is mainly used during nasal bone fracture, lateral, anterior skull base, and paranasal sinus.

Conclusion

As with the advancement in imaging techniques, imaging in head and neck have had a very positive impact and diagnosis of disease have become quite easy.

There are various diagnostic imaging that can be used in otolaryngology. Conventional x-rays are initial modality that is used but may yield confusing information leading to misdiagnosis.

Usually head and neck imaging mostly consist of MRI and CT imaging. Ultrasound is other alternative to CT for the low exposure of radiation. Other imaging techniques such as ultrasound and PET scans are used for special indication.

References

1. Patrick D. Barnes, Head and neck imaging, Pediatric Radiology: The Requisites.
2. Thomas J Vogl, Marc Harth, Petra Siebenhandl, Different imaging techniques in the head and neck: Assets and drawbacks. *World J Radiol* 2010 June 28; 2(6): 224-229 ,ISSN 1949-8470 (online)
3. Florian Dammann, Friedrich Bootz, Mathias Cohnen, Stefan Haßfeld, Marcos Tatagiba, Sabrina Kösling, Diagnostic Imaging Modalities in Head and Neck Disease, *Deutsches Ärzteblatt International | Dtsch Arztebl Int* 2014; 111:417-23.
4. Franz J. Wippold II, Head and Neck Imaging: The Role of CT and MRI, *JOURNAL OF MAGNETIC RESONANCE IMAGING* 25:453–465 (2007).
5. Maliha Sadick, Stefan O. Schoenberg, Karl Hoermann, Haneen Sadick, Current oncologic concepts and emerging techniques for imaging of head and neck squamous cell cancer, *GMS Current Topics in Otorhinolaryngology - Head and Neck Surgery* 2012, Vol. 11, ISSN 1865-1011 .
6. G. Hoeffner ,S.K. Mukherji, A. Srinivasan,J. Quint, Neuroradiology Back to the Future: Head and Neck Imaging, *AJNR* 33 _ Dec 2012 _ www.ajnr.org.
7. Rezul Karim, *Role of Ultrasonography in Otolaryngology*, Bengal Journal of Otolaryngology and Head Neck Surgery Vol. 24 No. 2 August, 2016.